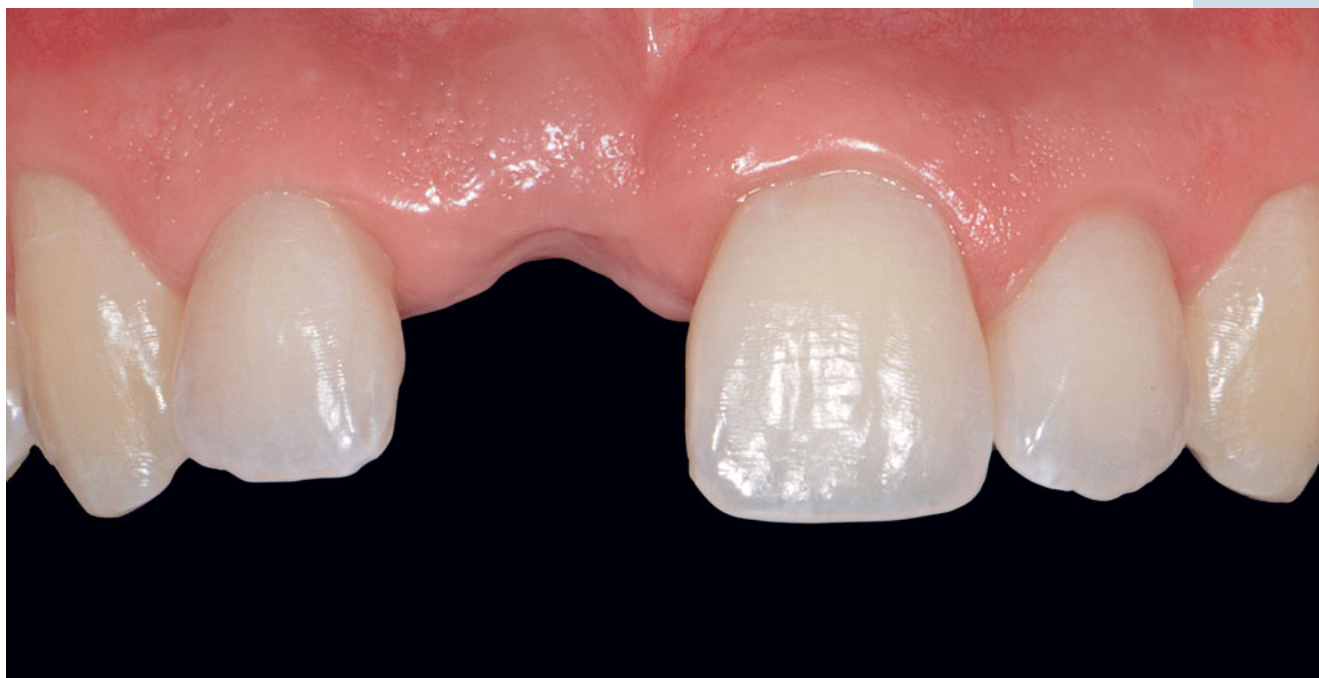

# Use of bovine bone mineral, titanium mesh, and a cross-linked collagen membrane in single implant site development at a maxillary central incisor tooth site: a 3-year follow-up case report

**Cobi Landsberg**, Dr Med Dent  
Private Practice, Tel Aviv, Israel



Correspondence to: [Dr Cobi Landsberg](#)  
53 Gordon Street, Tel Aviv, 6439414, Israel; Email: [cobilandsberg@gmail.com](mailto:cobilandsberg@gmail.com)

## Abstract

**Purpose:** It can be extremely challenging to replace a hopeless tooth in the maxillary central incisor area with an implant restoration, especially when the bony housing of the tooth is severely damaged. This condition is frequently found in teeth that have been severely traumatized in childhood. To avoid their extraction, these teeth might have been exposed to multiple compromised treatments and repeated traumatic injuries. When skeletal changes cease and implant therapy becomes an option, the surgeon may often find only remnants of the socket walls. This imposes difficulty when regenerating the missing tissues required for long-term functional and esthetic implant restoration. This article describes the unique anatomical, biological, and surgical considerations in the treatment of such a case.

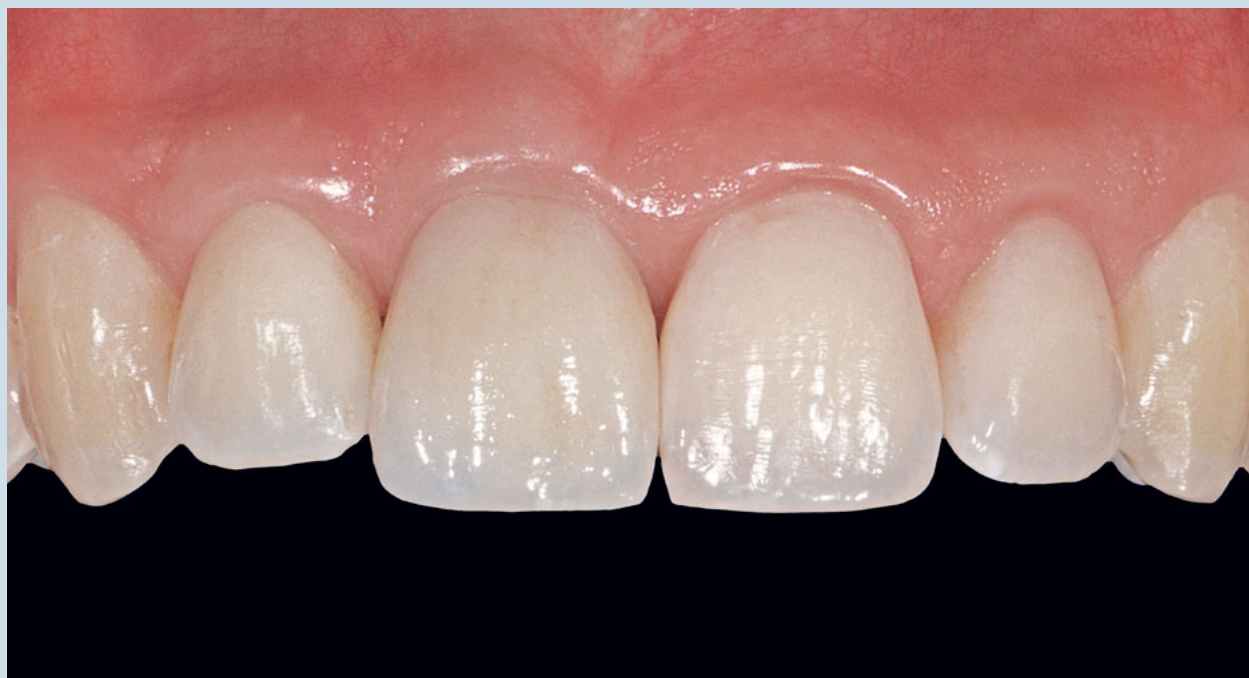**Materials and methods:** In the reconstruction of a safe bony housing around the implant, obliteration

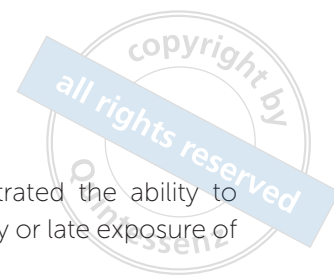of the incisive canal was followed by the use of bovine bone mineral (BBM) and titanium mesh (Ti-mesh) layered with a crosslinked collagen membrane. The soft tissue was augmented with a xenogeneic soft tissue matrix and further enhanced by a novel technique, the 'radial cuts technique.'

**Results:** Functional and esthetic implant restoration was successfully achieved. Follow-up of the patient took place for 2 years post-implant loading and 3 years post-ridge augmentation, after which the stability of the implant and surrounding tissue was demonstrated.

**Conclusion:** Enhanced functional and esthetic results may be achieved when BBM and Ti-mesh layered with a soft collagen membrane are utilized as augmentation materials in the esthetic zone. The key factors for success in this case were combining the advantages of the different materials with a carefully considered sequence of procedures.

(*Int J Esthet Dent* 2019;14:182–197)





## Introduction

The replacement of a missing maxillary incisor with an implant restoration is a routine dental procedure.<sup>1</sup> Functional and esthetic results may be predictably achieved when both bone and soft tissue foundations are guaranteed around the implant restoration.<sup>2-4</sup>

During implant placement, a three-dimensional ridge augmentation (3-DRA) procedure could be indicated for limited bone height. Various techniques and materials have been attempted for this procedure, including distraction osteogenesis,<sup>5</sup> particulate or block bone grafts,<sup>6,7</sup> bone grafts in combination with membranes,<sup>8</sup> and rhBMP-2 in combination with membranes<sup>9,10</sup> or without them.<sup>11</sup> The autogenous bone graft is considered the gold standard<sup>12</sup> but has limited use due to the amount of bone available and the associated morbidity. Bovine bone mineral (BBM) has been widely used for sinus augmentation,<sup>13</sup> socket preservation,<sup>14</sup> immediate implant surgery,<sup>15</sup> and horizontal and vertical ridge augmentation.<sup>16</sup> Its advantages include high osteoconductivity,<sup>17</sup> the ability to prevent ridge contraction,<sup>16</sup> and the association with a low failure rate of osseointegration.<sup>18</sup> Guided bone regeneration is a technique proposed for bone augmentation that uses a barrier membrane for space creation and maintenance.<sup>19</sup> In a 3-DRA procedure, titanium-reinforced expanded/nonexpanded polytetrafluoroethylene (ePTFE/PTFE) membrane is frequently used, mainly due to its effectiveness for space maintenance.<sup>20,21</sup> Nevertheless, membrane exposure with subsequent infection remains a major challenge for the ePTFE/PTFE material because of its impermeability. A better material for 3-DRA is porous titanium mesh (Ti-mesh), which not only allows for better space maintenance but often resists infection even when exposed.<sup>10,22-25</sup>

A study on the effect of overlaying Ti-mesh with collagen membrane for ridge

augmentation demonstrated the ability to completely prevent early or late exposure of the Ti-mesh.<sup>26</sup>

The purpose of this case report was to demonstrate the use of BBM and Ti-mesh overlaid with crosslinked collagen membrane for ridge augmentation and implant placement in the maxillary central incisor area, with a 2-year follow-up post-implant loading, and a 3-year follow-up post-augmentation.

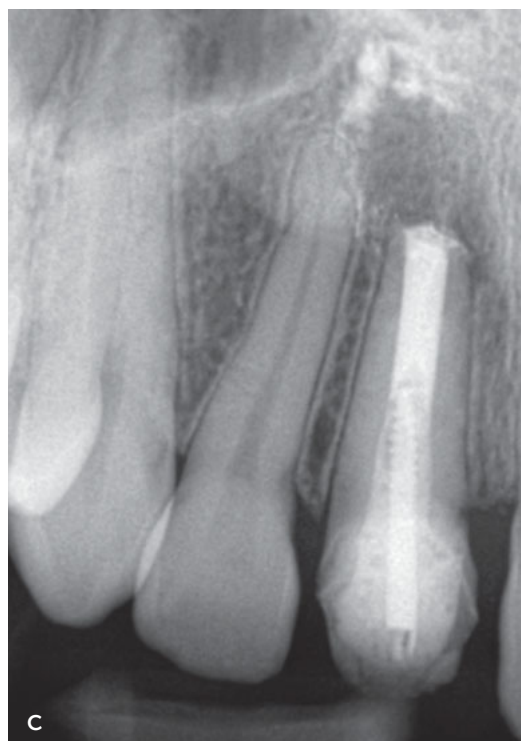
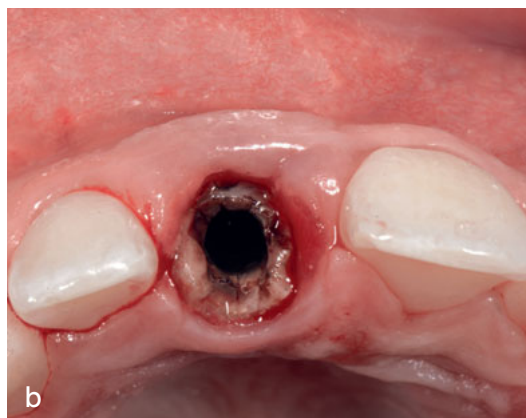
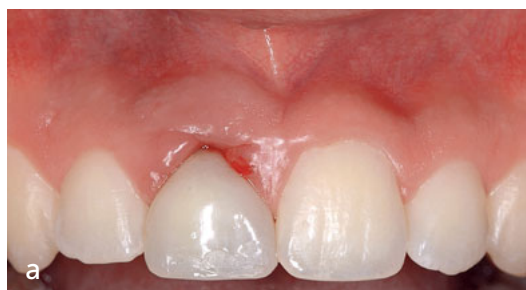## Case report

### Clinical examination

An 18-year-old male soldier presented to the clinic with an unstable temporary crown and an abutment weakly connected to a severely decayed root at tooth 11, surrounded by chronic gingival inflammation. The tooth had been previously traumatized when the patient was 12 years old. Since then, several root canal treatments and provisional restorations had been performed in an attempt to retain the tooth in place until adulthood. Radiographic examination revealed an apically resorbed root with a wide root canal filling and apical radiolucency. Radiopaque spots, suggestive of remnants of root canal filler materials, were found near the nasal floor (Fig 1).

### Treatment strategy

The patient's natural dentition was perfectly healthy and required no therapy except for the traumatized tooth and its surrounding inflamed gingiva. Implant restoration was an obvious reconstructive solution. However, because of the patient's military service obligations, it was decided to perform the treatment objectives in three main stages: 1) immediate tooth extraction to prevent further damage to the site; 2) ridge augmentation as soon as the patient's military



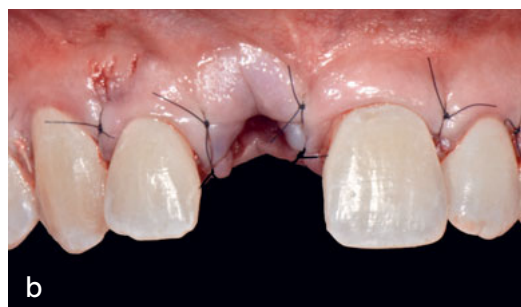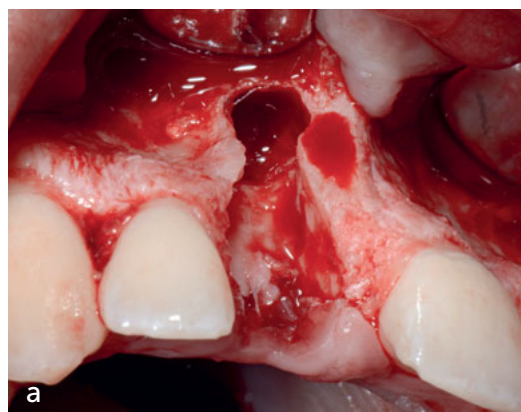
**Fig 1** (a) At presentation, an unstable provisional crown at the maxillary right incisor is surrounded by chronically inflamed gingiva. (b) The maxillary right incisor root is severely decayed and nonrestorable. (c) Radiograph showing a wide canal filling with apical and cervical radiolucency and radiopaque spots close to the nasal floor.

service restrictions would allow (which became possible only 2 years postextraction when he was 20 years old); and 3) implant placement when radiographic examinations indicated the cessation of skeletal growth (which was evident at age 21).

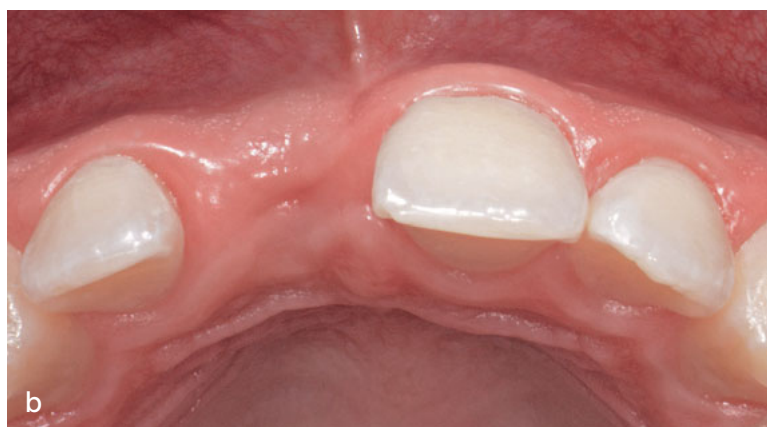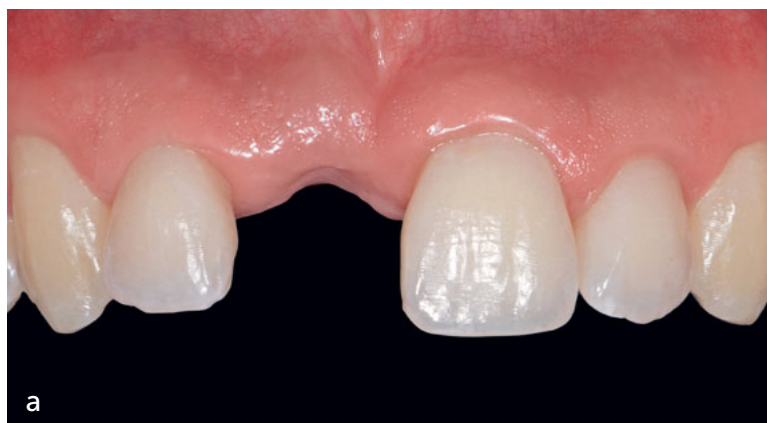### **Surgical therapy**

#### *Tooth extraction*

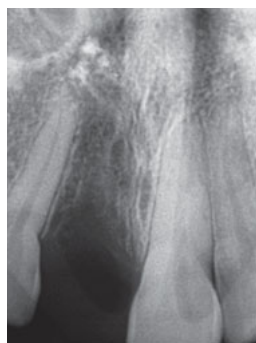
A wide full-thickness flap was elevated to maximize access for the complete removal of the granulation tissue and deeply located and possibly contaminated remnants of root canal filler materials associated with tooth 11. After full-thickness flap elevation, the tooth was removed, revealing an extraction socket with a destructed buccal plate that was thoroughly curetted (Fig 2a). However, despite improved accessibility, the remnants of the root canal filler seemed to be well embedded in the bone. A decision was made not to attempt its removal,



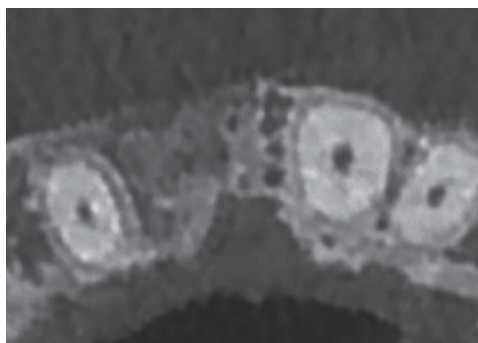
**Fig 2** (a) Upon extraction of the maxillary right incisor, the extraction socket is fully debrided. Note the full resorption of the buccal bone. (b) The buccal full-thickness flap is placed back in the original position and sutured with 6-0 polyamide sutures.



**Fig 3** (a) At 2 years postextraction, an almost normal gingival contour is observed from the buccal view. (b) Occlusal view shows moderate horizontal ridge resorption.



**Fig 4** Periapical radiograph shows postextraction slight radiopacity suggesting the presence of a thin ridge with poor or immature bone quality.



**Fig 5** CT scan shows the close proximity of the implant site to a wide incisive canal.

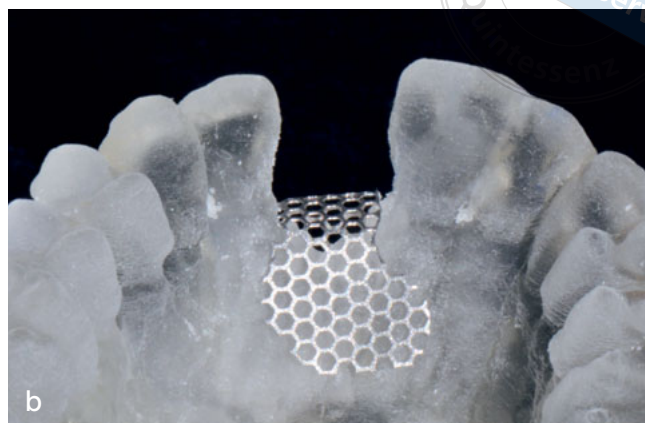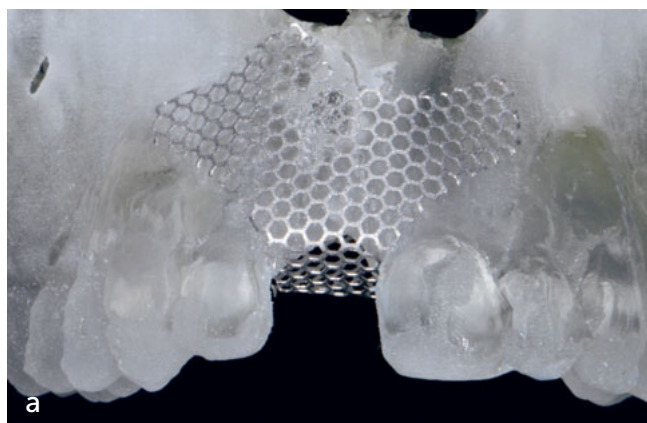which might have caused unnecessary further destruction to the bone. As planned, no regenerative therapy was implemented, and the flap was replaced and sutured with interrupted simple 6-0 polyamide sutures (Ethicon; Johnson & Johnson) (Fig 2b). The patient received an Essix retainer filled with composite at the missing tooth that served as an immediate detachable restoration.

The 2-year postextraction clinical examination revealed a combined vertical and horizontal ridge defect at the maxillary right central tooth site (Fig 3), with otherwise healthy dentition.

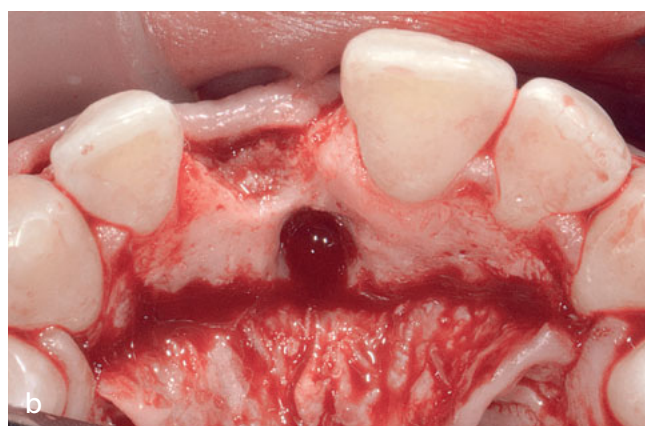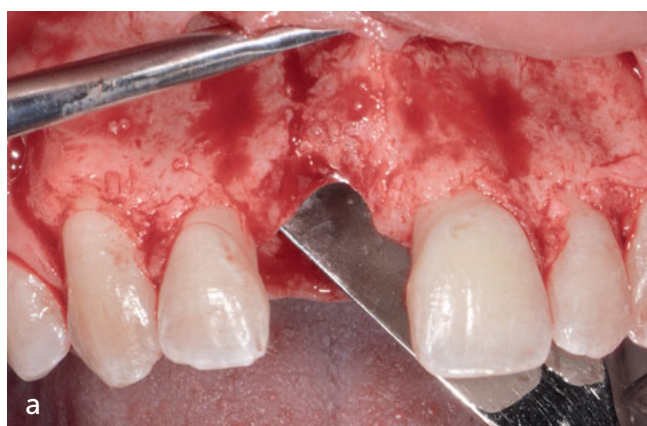Radiographic examination (Fig 4) showed increased radiopacity in the socket; however, there was marked radiolucency in the coronal third section. Remnants of root canal filling material could be seen close to the nasal floor. Computed tomography (CT) scans of the maxillary anterior area revealed a relatively narrow ridge due to buccal bone resorption and the presence of a wide nasopalatine canal, with its foramen located 4 to 5 mm apical of the alveolar crest (Fig 5).

## *Chairside preparation of the Ti-mesh*

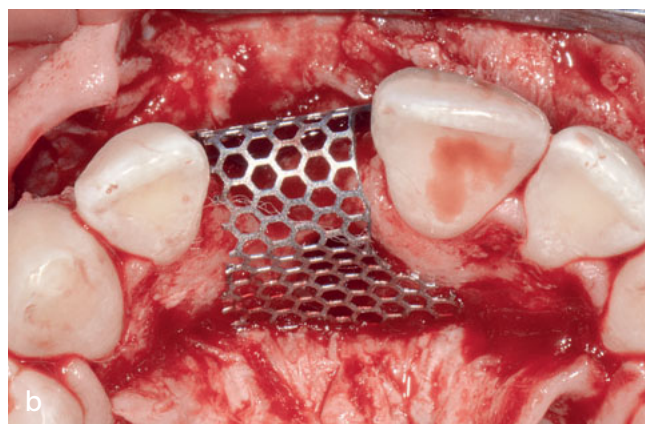
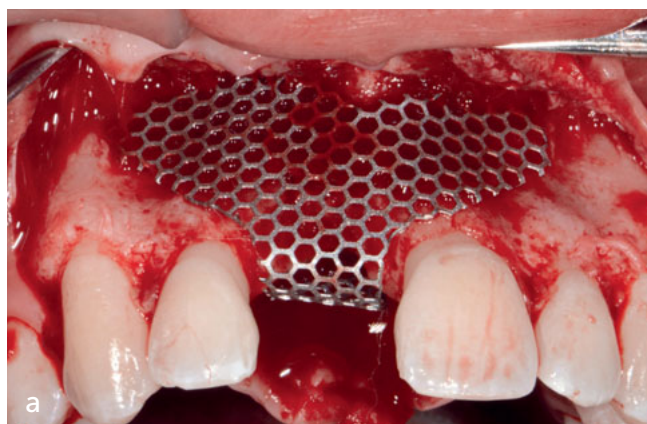
A stereolithic jaw model (Guide-3D; Object) was prepared to allow for a three-dimensional (3D) visualization of the defect anatomy and to serve as a working model for the presurgical preparation of a Ti-mesh (Biom-et). An 0.2-mm thick Ti-mesh (pore size 1.5 mm) was prepared to cover the defect and to create the space required for the grafted bone. On the buccal aspect, the mesh was extended sufficiently both apically and laterally to allow for the containment of all the grafted bone particles filling the ridge defect as well as to avoid injury to the neighboring roots with the fixation screws. Palatally, the mesh was extended well beyond the incisive canal foramen. This allowed for the stabilization of the bone to be grafted onto the palatal aspect and inside the incisive canal. Gaps of 2 to 3 mm from



**Fig 6** (a) A Ti-mesh is prepared on the 3D-printed acrylic model. It is extended for convenient fixation with screws placed remotely away from the neighboring roots. (b) Palatally, the Ti-mesh extends beyond the incisive canal opening, with its margins 2 to 3 mm distant from the roots.



**Fig 7** (a) Buccal view reveals moderate vertical bone resorption of the residual ridge at the maxillary right incisor site. (b) Occlusal view reveals moderate-to-advanced bone resorption at the maxillary right incisor area involving the incisive canal. Note the complete removal of incisive canal content.



**Fig 8** (a) Ti-mesh is placed to cover the defect, demonstrating the 3D ridge defect. (b) Ti-mesh covers the lingual part of the bone defect together with the nasopalatine canal opening.

the coronal (buccal and palatal) margins of the mesh, and 1.5 to 2 mm from the interproximal edges of the mesh to the neighboring roots, were meticulously maintained in order to provide the necessary space to reestablish the connective tissue attachment and thus a biologically stable marginal seal against bacterial contamination. These gaps would also allow full flap coverage over the mesh, thereby lowering the risk of its early clinical exposure (Fig 6).

## *Ridge augmentation*

Sulcular incisions were made both buccally and palatally from the right to the left canine, with papillary sparing and a crestal incision on the buccal slope over site 11. Distal line-angle vertical releasing incisions on the right and left canines allowed for proper visualization of and access to the osseous defect.

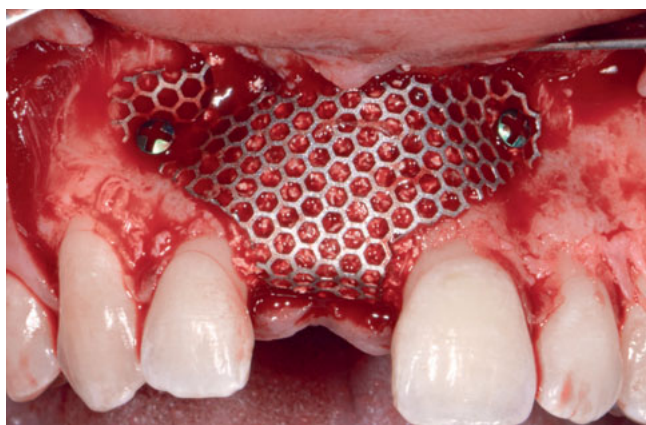
Full-thickness buccal and palatal flaps were elevated, revealing a large 3D defect extending to the nasopalatine canal. The area of the previous extraction socket and the incisive canal content were thoroughly curetted and debrided of all fibrous tissue remnants (Fig 7). A deep vestibular periosteal release was completed to provide flap mobility and to ensure tension-free suturing over the regeneration site. The pre-prepared mesh was examined *in situ* to ensure its exact preplanned position. Only minor additional trimming and bending of the mesh were necessary (Fig 8). BBM particles (Cerabone; Botiss) were placed to adequately fill the ridge defect. The Ti-mesh was adapted and fixed to the bone using three fixation screws (Biomet) (Fig 9). A resorbable cross-linked collagen membrane (Ossix Plus; Datum Dental) was placed in two to three layers to cover the entire mesh. Care was taken to retain its margins 1 to 2 mm away from the roots to prevent interference with the reestablishment of connective tissue attachment to the roots. The created gaps be-

tween the Ti-mesh and the layering collagen membrane and the roots could also serve as pathways for periosteal progenitor cells and blood supply to contribute bone-forming cells and essential nutrients to the regenerative process taking place at the most superficial bone graft layer immediately under the Ti-mesh (Fig 10). The surgical site was sutured with a combination of 5-0 d-PTFE horizontal and vertical mattress (Golnit) and 6-0 polyamide (Ethicon) simple interrupted sutures (Fig 11). This combination of suture materials enabled close adaptation of the flaps and interproximal papillae during the early healing phase. Postoperative care was then reviewed with the patient.

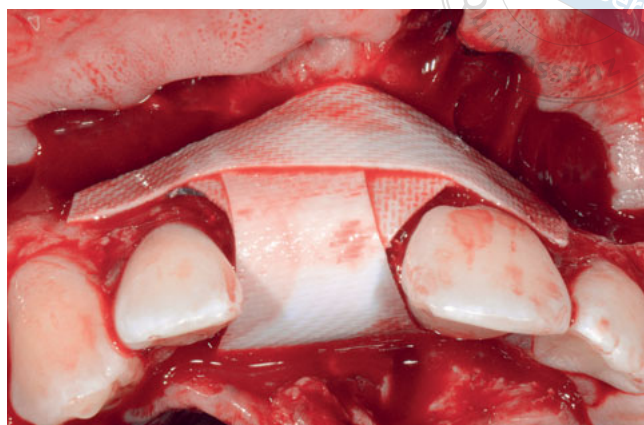
Healing was uneventful, with complete soft tissue coverage of the entire augmented area. However, at 9 months postsurgery the ridge had not regained the complete root convexity configuration (Fig 12). CT scanning revealed no signs of slight vertical or horizontal bone resorption. Supracrestal measurement showed a vertical bone gain of 8 mm. Horizontal bone gain measurements were recorded at the original crestal height (11 mm), and at the newly regenerated crestal height (7 mm). Using Msoft software (Swissmeda), a 13-mm long and 4.1-mm wide implant was planned for the left incisor site (Fig 13).

## *Implant placement and soft tissue augmentation*

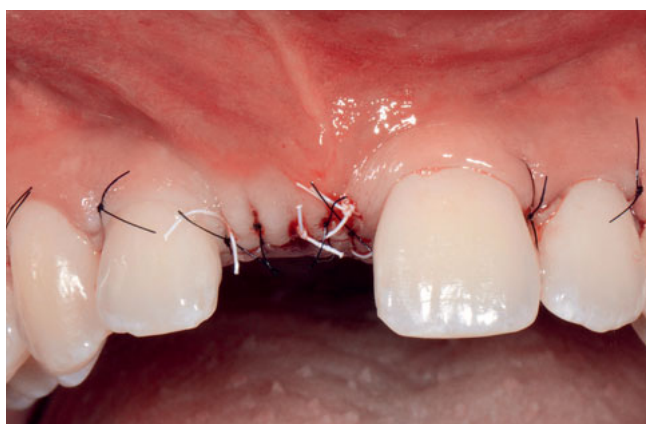Full-thickness buccal and palatal flaps were elevated using a sharp periosteal elevator to gently expose the regenerated area. The collagen membrane that presented in its entirety was removed to immediately expose the tightly fixated mesh (Fig 14). A blunt periosteal elevator was used to easily lift the mesh from the regenerated bone. Attached to the mesh was very thin transparent soft tissue. Except for a few free bone particles on the most coronal part of the augmented area,



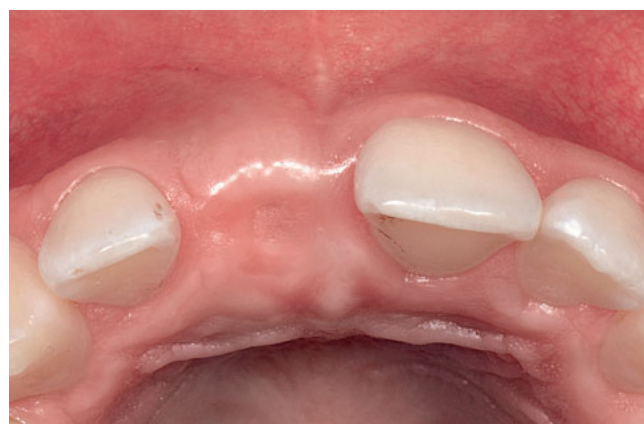**Fig 9** Bone substitute is placed under the Ti-mesh, which is fixed to the recipient bone. Note the edges of the mesh are approximately 1 to 2 mm away from the root surfaces.



**Fig 10** Three overlapping layers of the resorbable membrane are placed to fully cover the Ti-mesh. Note the membrane edges are 1 to 3 mm away from the root surfaces.

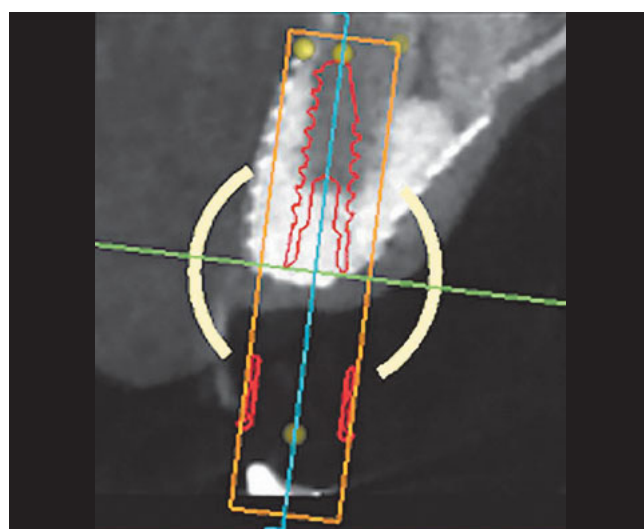


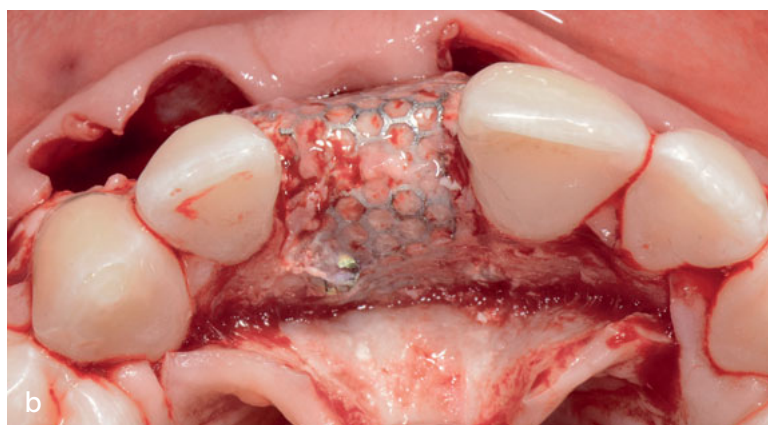
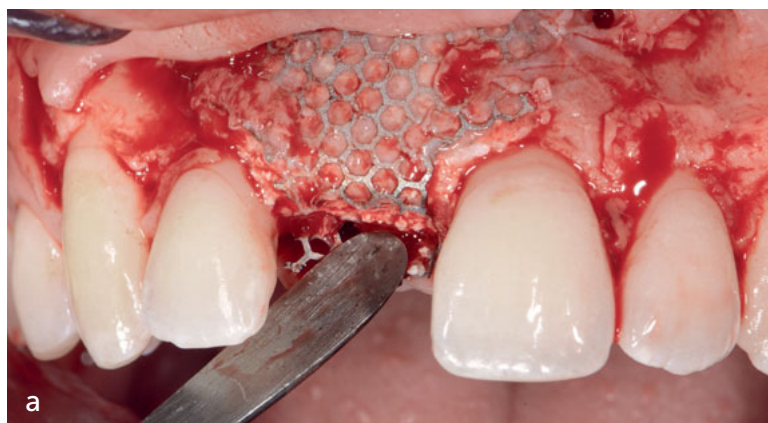**Fig 11** The buccal flap is advanced and sutured to the palatal flap to fully cover the regenerating site without tension.



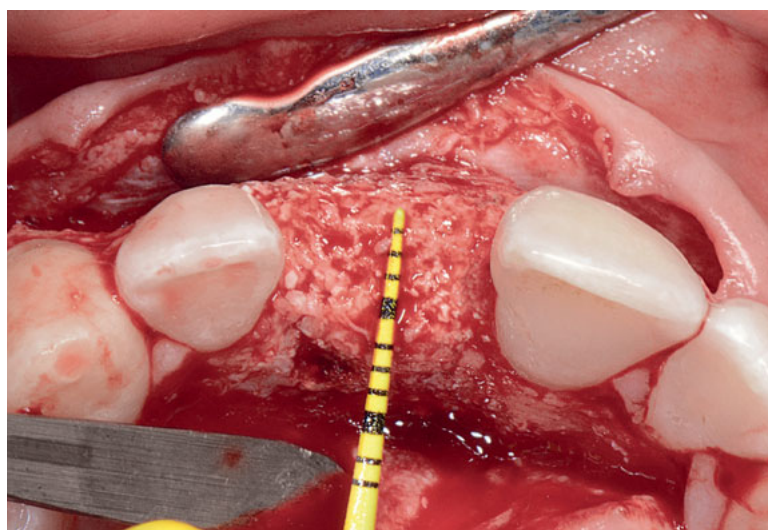
**Fig 12** At 9-months post-regenerative procedure there is uneventful healing with no inflammation detected.

**Fig 13** CT scan shows the image of the planned implant at the augmented site. Note the supracrestal bone gain of 11 mm at the presurgical crestal height and 7 mm at the newly formed height.





**Fig 14** (a) Buccal view showing the exposed Ti-mesh. (b) Occlusal view showing the exposed Ti-mesh.



**Fig 15** Upon removal of the Ti-mesh, a newly formed wide and high ridge is shown.

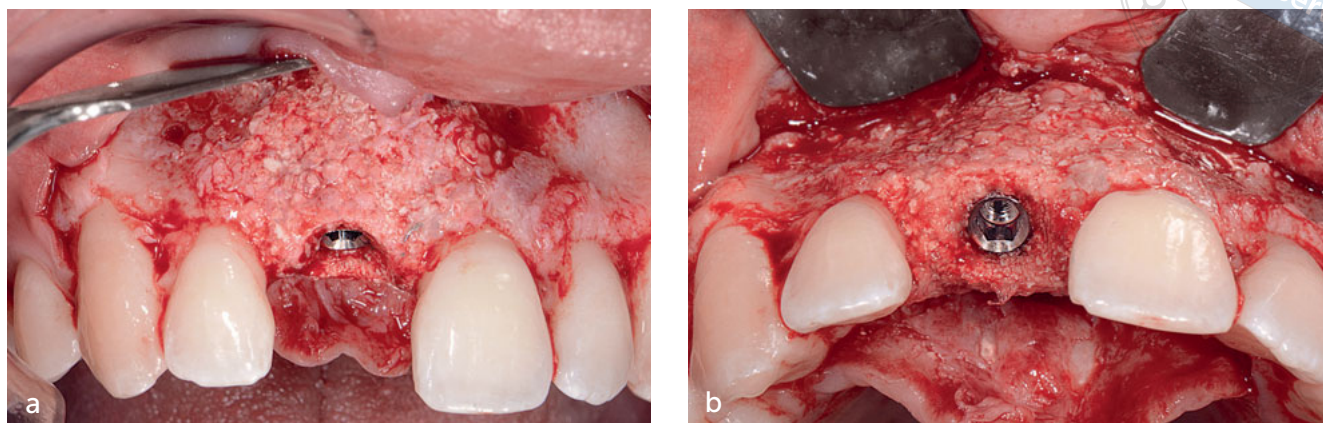
the exposed bone graft showed a stable and sound structure with adequate 3D topography suitable for ideal implant positioning (Fig 15). After slight osteoplasty to create a wider crestal table and to obtain the ridge scalloping contour, a 4-mm wide and 13-mm long (ZimmerBiomet) implant was placed using an insertion torque lower than 30 Ncm (Fig 16). To improve the soft tissue profiles of the ridge, a xenogeneic soft tissue substitute (Mucoderm; Botiss) was placed at the implant site, fully submerged under the everted and sutured mucosal flaps (Fig 17).

## *Implant exposure and transmucosal profiles development*

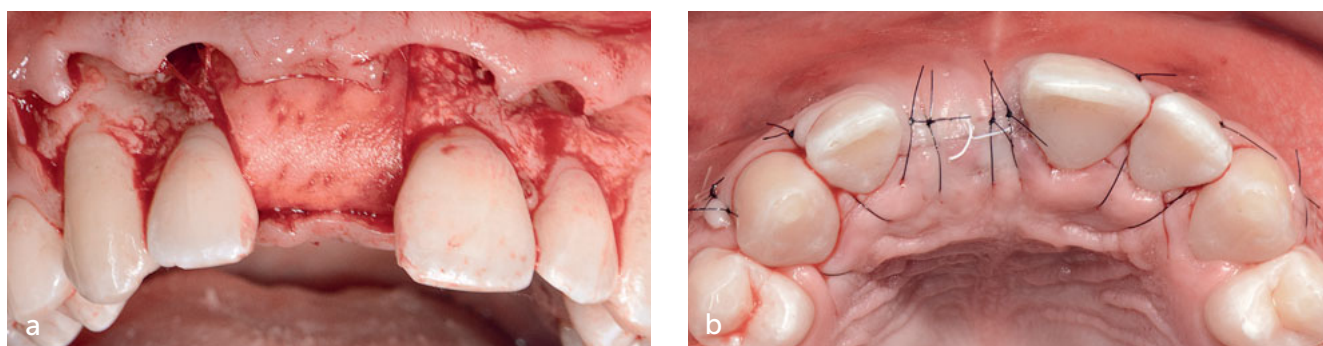
After 3 months, a slight but significant improvement of the soft tissue volume was noted (Fig 18). The implant was exposed using a crestal incision across the ridge, and a healing abutment was connected, slightly pushing the buccal flap labially. After 1 month, the healing abutment was removed and a novel technique (the 'radial cuts technique' –presented by the author to the Israeli Periodontal and Osseointegration Society Annual Meeting in Tel Aviv, Israel, in February 2017) using short incisional cuts around the created soft tissue sleeve was made to facilitate the complete seating of the screw-retained provisional crown on the implant (Fig 19).

## *Final restoration*

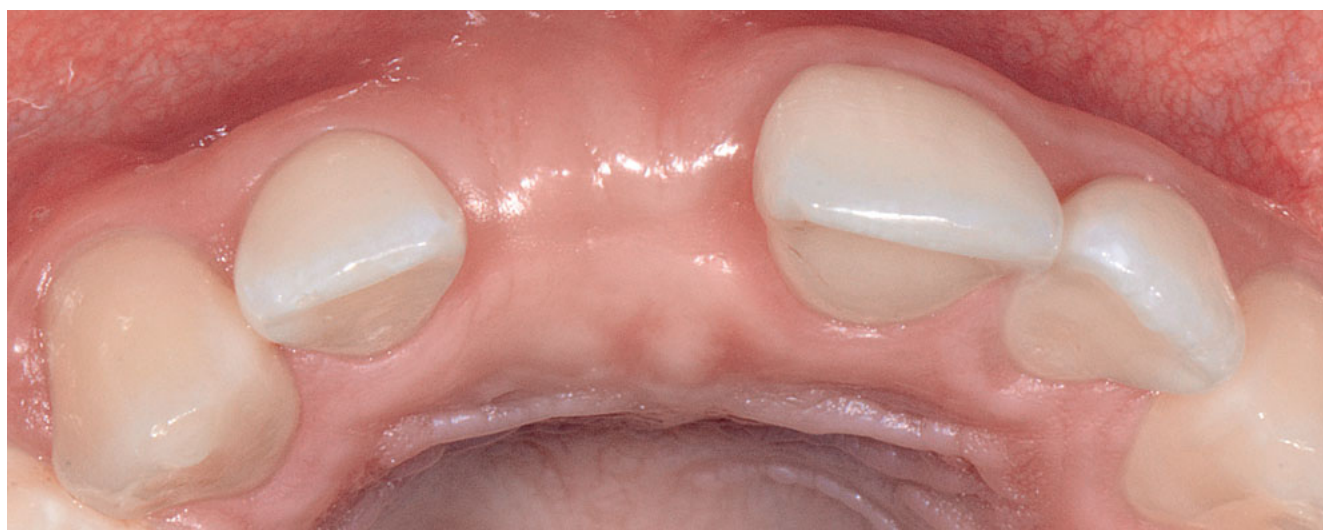After 2 months, with the periimplant transmucosal tissue having completed maturation, a screw-retained fixed porcelain-layered zirconia crown was connected to the implant. The immediate clinical appearance of the maxillary anterior dentition showed a well-integrated final crown surrounded by nicely contoured periimplant soft tissue (Fig 20). Radiographically, the implant surfaces appeared to be in close contact with



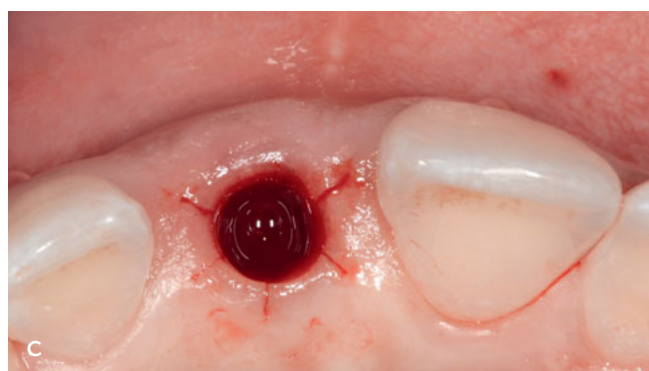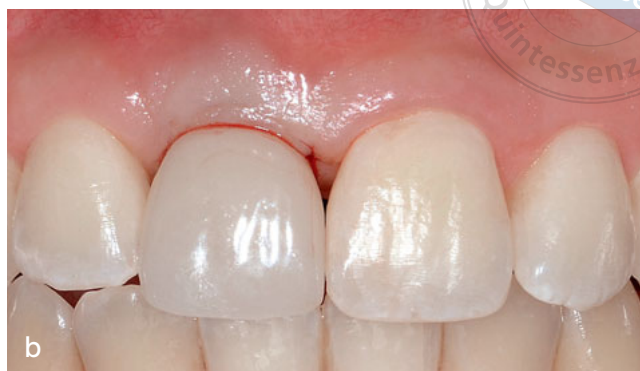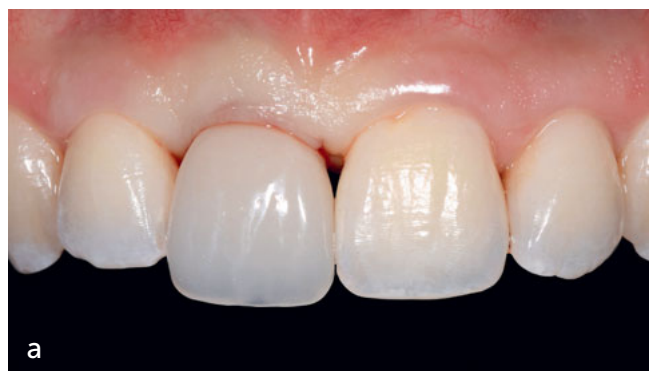**Fig 16** (a) The newly regenerated buccal bone is slightly reduced to achieve the desired scalloped marginal crestal contour, and the implant is placed level with the bone crest. (b) Occlusal-buccal view shows the implant well situated in the regenerated ridge.



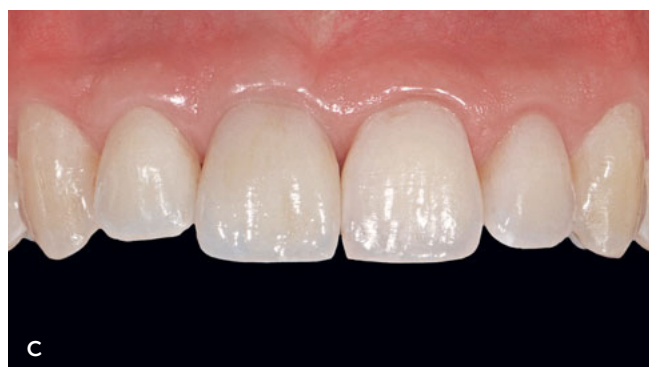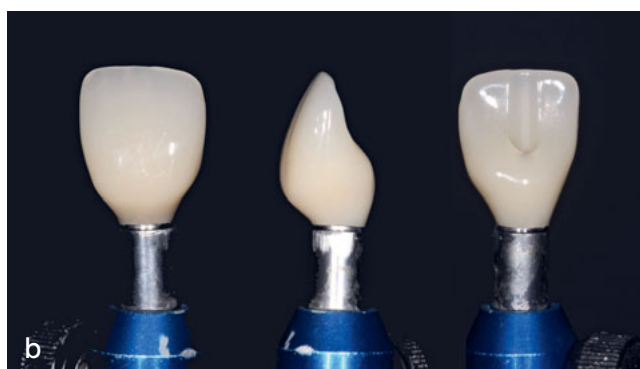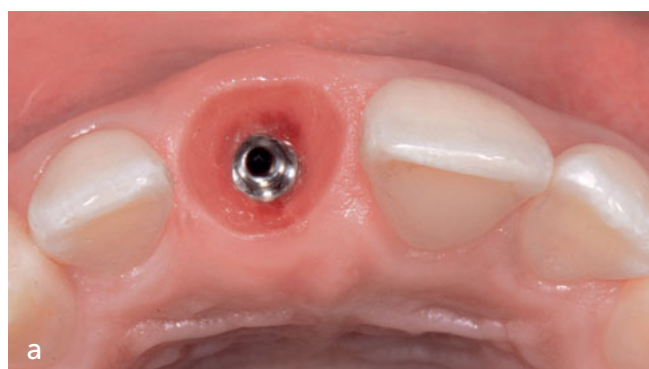**Fig 17** (a) A xenogenic soft tissue substitute is placed to further augment the ridge. (b) Complete flap closure over the implant and soft tissue graft.



**Fig 18** Healing at 3 months post-implant placement. Note the slight but significant soft tissue gain.



**Fig 19** (a) A transitional acrylic crown with slightly wider profiles than the transmucosal profiles is unable to sit on and connect to the implant. (b) In a circular manner around the soft tissue sleeve, short incisional cuts traversing from the outer surface to the implant head ('radial cuts technique') are made to facilitate the seating and connecting of the provisional crown to the implant. (c) The provisional crown is fully seated and connected to the implant.



**Fig 20** (a) Occlusal view shows ultimate prosthetically designed transmucosal tissue profiles with a healthy appearance. (b) Final zirconia crown presents concave emergence profiles. (c) Frontal view shows the final crown situated in a well-contoured and healthy soft tissue housing.

the surrounding regenerated bone. However, a loose bony appearance was noted, with remnants of an old root canal filler material apical to the implant apex (Fig 21).

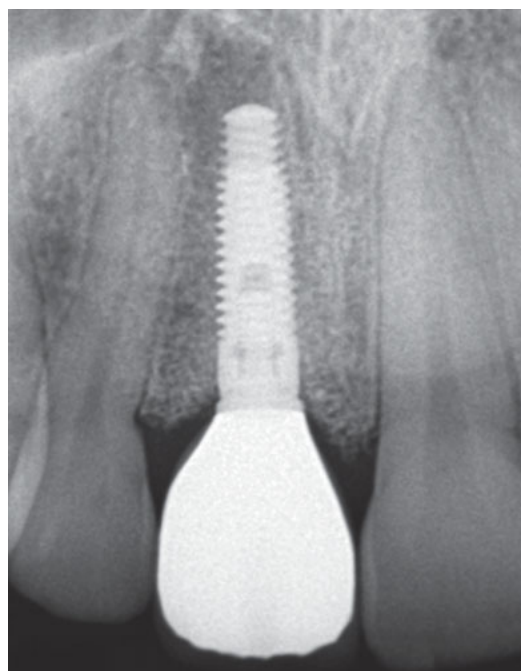
### Maintenance therapy and follow-up

The patient was instructed to practice tooth cleansing with a soft toothbrush and unwaxed dental floss twice daily. Supportive periodontal and periimplant treatment included strict 3-month-interval hygienic sessions and yearly clinical and radiographic examinations with special attention to the implant restoration.

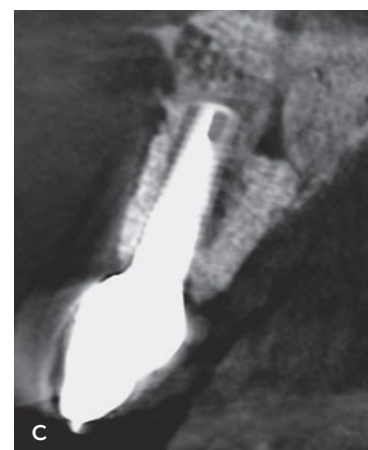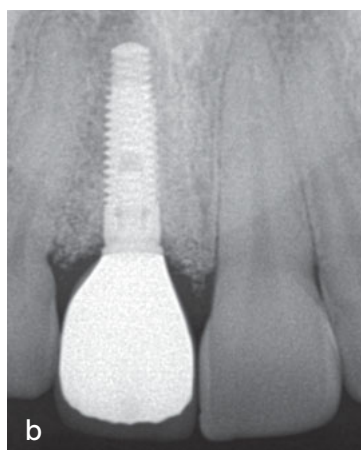
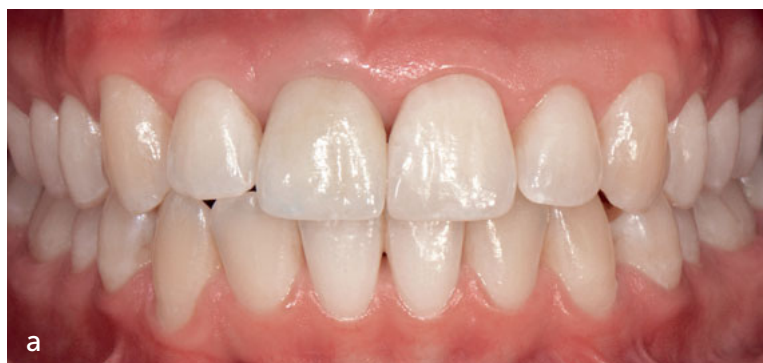Clinical and radiographic examinations, including CT scans, revealed functional and esthetic stability with increasing apical radio-density 3-years post-ridge augmentation (Fig 22).

### Discussion

Numerous studies and case reports show the successful use of Ti-mesh for implant site development in the treatment of severely atrophied ridges.<sup>10,22-37</sup> Most studies use Ti-mesh combined with autogenous bone as the only material or part of the grafting material for vertical ridge augmentation (VRA).<sup>23-25,29,31-36</sup> Although considered the gold standard, autogenous bone is associated with increased patient morbidity



**Fig 21** Radiograph at completion of treatment shows well-integrated implant with a solid presence of regenerated crestal bone. Note the loose bony appearance and the remnants of old root canal treatment apical of the implant.



**Fig 22** (a) After 3 years, the clinical picture demonstrates stable tissue profiles. (b) At the 3-year follow-up, the radiographic view shows solid stable bone profiles. Note the advanced calcification of the previously inflamed periapical area. (c) At the 3-year follow-up, the CT scan shows the full representation of the regenerated buccal bone with stable bony profiles buccally and palatally of the implant.



and extended surgical time due to graft harvesting. The present case is one of the few clinical reports that used xenograft and Ti-mesh for VRA.<sup>22</sup> Xenograft was used since it possesses osteoconductive properties,<sup>17</sup> eliminates a second surgical donor site, and minimizes postoperative ridge contraction.<sup>16</sup> However, xenograft is a slow, almost non-resorbing material that may not have the capacity to osseointegrate and resist inflammatory processes as effectively as grafted allogeneous or autogenous bone. Therefore, its long-term success, especially in VRA, should be further investigated.

It is commonly recognized that the benefits of Ti-mesh include easy handling and shaping, biocompatibility, and excellent mechanical properties for rigid stabilization of the graft material. This allows excellent integration of the bone graft into the recipient site, and enables successful treatment of all types and sizes of large 3D bony defects.<sup>37</sup> However, although Ti-mesh is stable and well-adapted to the bone-grafted defect, exposure after soft tissue dehiscence ranges from 10.5% to 80% in studies with 7 to 24 participating patients.<sup>23,31,32,34,35,38,39</sup> Clinicians report that if exposure of the mesh occurs after an initial 2 to 6 weeks of healing, the soft tissue dehiscences are generally well tolerated, and apparently do not have a negative influence on implant placement.<sup>23,24,31,35,39</sup> Notwithstanding, soft tissue loss may have a significant negative impact on the soft tissue contours. In particular, the maxillary anterior areas may exhibit poor esthetic outcomes. Therefore, it is mandatory to smooth all sharp mesh edges with a round diamond bur to minimize the occurrence of early or late mesh exposure. It has also been suggested to layer the mesh with either platelet-rich plasma 'paste'<sup>40</sup> or with a resorbable collagen membrane.<sup>26</sup> In the present case, a cross-linked collagen membrane was used, which evidently, if not exposed to the oral cavity, may remain intact

for at least 6 months.<sup>41</sup> It is believed that the smooth outer membrane surface prevents potential injury to the covering soft tissue, thus minimizing its potential exposure. Additionally, covering the porous mesh with a cell occlusive membrane (ie, implementing the well-proven biological principle of guided tissue regeneration)<sup>19,42</sup> may facilitate bone ingrowth originating from the recipient jaw bone. Progenitor cells and blood supply that originate from the periosteum may still invade the regenerating bone via the gaps remaining between the membrane and the roots. This may contribute to bone regeneration, especially in the grafted layer immediately under the Ti-mesh, which could be crucial mainly in large bone defects where the distant part of the grafted bone might be more than 3 mm away from the native bone. In this respect, a membrane that is cell occlusive to fibroblasts but not to mesenchymal stem cells and that does not block flap-originated blood supply might function superiorly. An additional advantage of using a collagen membrane is that it prevents flap tissue from interweaving in the porous mesh and connecting to the bone. Thus, mesh separation and retrieval from the bone becomes convenient and rapid.

In their study of 17 patients using Ti-mesh (50% autogenous bone, 50% BBM), Proussaefs and Lozada<sup>32</sup> measured  $2.56 \pm 1.32$  mm and  $3.75 \pm 1.33$  mm vertical and horizontal reconstruction, respectively. When only vertical height changes using Ti-mesh (and autogenous bone blocks) were measured in 18 patients, Rocuzzo et al<sup>24</sup> found a mean of 4.8 mm (range 4 to 7 mm) in vertical bone augmentation. In 16 patients,  $3.71 \pm 1.24$  mm and  $4.16 \pm 0.59$  mm in vertical and horizontal change, respectively, using Ti-mesh (70% autogenous, 30% BBM) was measured by Pieri et al.<sup>34</sup> In 24 patients, Corinaldesi et al<sup>35</sup> measured a vertical bone gain of  $8.6 \pm 4.0$  mm using Ti-mesh and au-

togenous bone mixed either with 1:1 or 4:1 BBM and recombinant human platelet-derived growth factor BB. In a recent case report, Levine and McAllister<sup>37</sup> measured 7 mm horizontal bone gain using Ti-mesh and a cellular allograft containing adult mesenchymal stem cells.

A mean vertical gain (using various bone grafting materials) of 2.56 to 6 mm is provided with the Ti-mesh technique.<sup>37</sup> Exceptional vertical gain of 8.6 mm was reported by Funato et al,<sup>39</sup> and 13.7 mm by Louis et al.<sup>33</sup> The reported mean horizontal bone gain using the Ti-mesh technique is approximately 4 mm. However, Levine and McAllister<sup>37</sup> reported a pronounced gain of 7 mm.

With this data, the vertical bone gain of 8 mm, together with the maximal horizontal gain of 11 mm reported in the present case using Ti-mesh and BBM, may be considered in the high range. The author believes that achieving this distinct 3D bone gain that proved stable over 3 years may be mainly attributed to the following factors:

1. Obliteration of the nasopalatine canal (an anatomic obstacle to regeneration).<sup>43,44</sup>
2. Use of a slow, resorbable, and dimensionally stable bone substitute (BBM) as a grafting material.
3. Use of Ti-mesh as an easily designed solid space maintainer and wound stabilizer.
4. Use of a slow, resorbable membrane as a guided tissue regeneration material.
5. Allowing flap blood supply and periosteal progenitor cell participation in the periphery of the regenerating bone.
6. Maintaining complete soft tissue coverage during the relatively prolonged 9-month regenerative process.

Since there is no miraculous material or procedure that 'does it all,' the author strongly believes that by recognizing and combin-

ing the advantages of different available materials and methods, substantial bone gain can be achieved that will serve as a solid, long-lasting foundation for an esthetic outcome.

## Conclusion

As with every successful 3D regeneration of the implant's 'bony housing' in the esthetic zone, it is mandatory to augment the soft tissue to ensure the buildup of a 'soft tissue housing' with high functional and esthetic qualities. In this case, it was decided to augment the ridge with xenogenic soft tissue substitute at the time of implant placement. This resulted in layering the bone with abundant soft tissue at the buccal and interproximal aspects where it is functionally and esthetically needed. Therefore, except for punching out the covering mucosa, no complex flap manipulations or additional soft tissue grafting were necessary at the time of implant exposure. Only minor tissue cuts (as described) were made on connecting the transitional screw-retained crown to the implant. These cuts facilitated crown placement and the establishment of the final desired functional and esthetic transmucosal profiles.

Finally, the treatment concept as described in this article combines technique-sensitive hard and soft tissue augmentation procedures. Further investigation is required to prove its predictive efficacy in gaining immediate as well as long-term successful results.

## Acknowledgment

The author would like to thank Dr Yaron Blasbalg and MDT Yuli Kuperstein for the prosthetic treatment.

## References

1. den Hartog L, Slater JJ, Vissink A, Meijer HJ, Raghoobar GM. Treatment outcome of immediate, early and conventional single-tooth implants in the aesthetic zone: a systematic review to survival, bone level, soft-tissue, aesthetics and patient satisfaction. *J Clin Periodontol* 2008;35: 1073–1086.
2. Arunyanak SP, Pollini A, Ntounis A, Morton D. Clinician assessments and patient perspectives of single-tooth implant restorations in the esthetic zone of the maxilla: A systematic review. *J Prosthet Dent* 2017;118:10–17.
3. Sullivan RM. Perspectives on esthetics in implant dentistry. *Compend Contin Educ Dent* 2001;22:685–692.
4. Bichacho N. Achieving optimal gingival esthetics around restored natural teeth and implants. Rationale, concepts, and techniques. *Dent Clin North Am* 1998;42: 763–780.
5. Chiapasco M, Zaniiboni M, Rimondini L. Autogenous onlay bone grafts vs. alveolar distraction osteogenesis for the correction of vertically deficient edentulous ridges: A 2-4-year prospective study on humans. *Clin Oral Implants Res* 2007;18:432–440.
6. Proussaefs P, Lozada J, Kleinman A, Rohrer MD. The use of ramus autogenous block grafts for vertical alveolar ridge augmentation and implant placement: a pilot study. *Int J Oral Maxillofac Implants* 2002;17:238–248.
7. Wang HL, Misch C, Neiva RF. "Sandwich" bone augmentation technique: rationale and report of pilot cases. *Int J Periodontics Restorative Dent* 2004;24:232–245.
8. Simion M, Jovanovic SA, Trisi P, Scarano A, Piattelli A. Vertical ridge augmentation around dental implants using a membrane technique and autogenous bone or allografts in humans. *Int J Periodontics Restorative Dent* 1998;18:8–23.
9. Jovanovic SA, Hunt DR, Bernard GW, Spiekermann H, Wozney JM, Wikesjö UM. Bone reconstruction following implantation of rhBMP-2 and guided bone regeneration in canine alveolar ridge defects. *Clin Oral Implants Res* 2007;18:224–230.
10. Misch CM. Bone augmentation of the atrophic posterior mandible for dental implants using rhBmp-2 and titanium mesh: clinical technique and early results. *Int J Periodontics Restorative Dent* 2011;31:581–589.
11. Schopper C, Moser D, Spassova E, et al. Bone regeneration using a naturally grown HA/TCP carrier loaded with rhBMP-2 is independent of barrier membrane effects. *J Biomed Mater Res A* 2008;85:954–963.
12. Gongloff RK, Cole M, Whitlow W, Boyne PJ. Titanium mesh and particulate cancellous bone and marrow grafts to augment the maxillary alveolar ridge. *Int J Oral Maxillofac Surg* 1986;15:263–268.
13. Wang F, Zhou W, Monje A, Huang W, Wang Y, Wu Y. Influence of healing period upon bone turn over on maxillary sinus floor augmentation grafted solely with deproteinized bovine bone mineral: A prospective human histological and clinical trial. *Clin Implant Dent Relat Res* 2017;19:341–350.
14. de Barros RR, Novaes AB Jr, de Carvalho JP, de Almeida ALG. The effect of a flapless alveolar ridge preservation procedure with or without a xenograft on buccal bone crest remodeling compared by histomorphometric and microcomputed tomographic analysis. *Clin Oral Implants Res* 2017;28: 938–945.
15. Caneva M, Botticelli D, Morelli F, Cesaretti G, Beolchini M, Lang NP. Alveolar process preservation at implants installed immediately into extraction sockets using deproteinized bovine bone mineral – an experimental study in dogs. *Clin Oral Implants Res* 2012;23:789–796.
16. Nart J, Barallat L, Jimenez D, et al. Radiographic and histological evaluation of deproteinized bovine bone mineral vs. deproteinized bovine bone mineral with 10% collagen in ridge preservation. A randomized controlled clinical trial. *Clin Oral Implants Res* 2017;28:840–848.
17. Jensen SS, Aaboe M, Janner SF, et al. Influence of particle size of deproteinized bovine bone mineral on new bone formation and implant stability after simultaneous sinus floor elevation: a histomorphometric study in minipigs. *Clin Implant Dent Relat Res* 2015;17:274–285.
18. Xavier SP, Santos T de S, Sehn FP, Silva ER, Garcez-Filho J de A, Martins-Filho PR. Maxillary sinus grafting with fresh frozen allograft versus bovine bone mineral: A tomographic and histological study. *J Craniomaxillofac Surg* 2016;44:708–714.
19. Wang HL, Boyapati L. "PASS" principles for predictable bone regeneration. *Implant Dent* 2006;15:8–17.
20. Simion M, Trisi P, Piattelli A. Vertical ridge augmentation using a membrane technique associated with osseointegrated implants. *Int J Periodontics Restorative Dent* 1994;14: 496–511.
21. Simion M, Fontana F, Rasperini G, Maiorana C. Vertical ridge augmentation by expanded-polytetrafluoroethylene membrane and a combination of intra-oral autogenous bone graft and deproteinized anorganic bovine bone (Bio Oss). *Clin Oral Implants Res* 2007;18:620–629.
22. Artzi Z, Dayan D, Alpern Y, Nemcovsky CE. Vertical ridge augmentation using xenogenic material supported by a configured titanium mesh: clinicohistopathologic and histochemical study. *Int J Oral Maxillofac Implants* 2003;18:440–446.
23. Proussaefs P, Lozada J, Kleinman A, Rohrer MD, McMillan PJ. The use of titanium mesh in conjunction with autogenous bone graft and inorganic bovine bone mineral (bio-oss) for localized alveolar ridge augmentation: a human study. *Int J Periodontics Restorative Dent* 2003;23: 185–195.
24. Rocuzzo M, Ramieri G, Spada MC, Bianchi SD, Berrone S. Vertical alveolar ridge augmentation by means of a titanium mesh and autogenous bone grafts. *Clin Oral Implants Res* 2004;15:73–81.
25. Miura K, Matsui K, Kawai T, et al. Octacalcium phosphate collagen composites with titanium mesh facilitate alveolar augmentation in canine mandibular bone defects. *Int J Oral Maxillofac Surg* 2012;41:1161–1169.
26. Degidi M, Scarano A, Piattelli A. Regeneration of the alveolar crest using titanium micromesh with autologous bone and a

resorbable membrane. *J Oral Implantol* 2003;29:86–90.

27. Gargiulo EA, Ziter WD, Messina JR, Goltry RR. Use of titanium mesh and autogenous bone marrow in the repair of a nonunited mandibular fracture: report of case and review of the literature. *J Oral Surg* 1973;31:371–376.

28. Boyne PJ, Cole MD, Stringer D, Shafqat JP. A technique for osseous restoration of deficient edentulous maxillary ridges. *J Oral Maxillofac Surg* 1985;43:87–91.

29. von Arx T, Hardt N, Walkamm B. The TIME technique: a new method for localized alveolar ridge augmentation prior to placement of dental implants. *Int J Oral Maxillofac Implants* 1996;11:387–394.

30. Mengel R, Meer C, Flores-de-Jacoby L. The treatment of uncoated and titanium nitride-coated abutments with different instruments. *Int J Oral Maxillofac Implants* 2004;19:232–238.

31. Rocuzzo M, Ramieri G, Bunino M, Berrone S. Autogenous bone graft alone or associated with titanium mesh for vertical alveolar ridge augmentation: a controlled clinical trial. *Clin Oral Implants Res* 2007;18:286–294.

32. Proussaefs P, Lozada J. Use of titanium mesh for staged localized alveolar ridge augmentation: clinical and histologic-histomorphometric evaluation. *J Oral Implantol* 2006;32:237–247.

33. Louis PJ, Gutta R, Said-Al-Naief N, Bartolucci AA. Reconstruction of the maxilla and mandible with particulate bone graft and titanium mesh for implant placement. *J Oral Maxillofac Surg* 2008;66:235–245.

34. Pieri F, Corinaldesi G, Fini M, Aldini NN, Giardino R, Marchetti C. Alveolar ridge augmentation with titanium mesh and a combination of autogenous bone and anorganic bovine bone: a 2-year prospective study. *J Periodontol* 2008;79:2093–2103.

35. Corinaldesi G, Pieri F, Sapigni L, Marchetti C. Evaluation of survival and success rates of dental implants placed at the time of or after alveolar ridge augmentation with an autogenous mandibular bone graft and titanium mesh: A 3- to 8-year retrospective study. *Int J Oral Maxillofac Implants* 2009;24:1119–1128.

36. Miyamoto I, Funaki K, Yamauchi K, Kodama T, Takahashi T. Alveolar ridge reconstruction with titanium mesh and autogenous particulate bone graft: computed tomography-based evaluations of augmented bone quality and quantity. *Clin Implant Dent Relat Res* 2012;14:304–311.

37. Levine RA, McAllister BS. Implant site development using Ti-mesh and cellular allograft in the esthetic zone for restorative-driven implant placement: a case report. *Int J Periodontics Restorative Dent* 2016;36:373–381.

38. Her S, Kang T, Fien MJ. Titanium mesh as an alternative to a membrane for ridge augmentation. *J Oral Maxillofac Surg* 2012;70:803–810.

39. Funato A, Ishikawa T, Kitajima H, Yamada M, Moroi H. A novel combined surgical approach to vertical alveolar ridge augmentation with titanium mesh, resorbable membrane, and rh-PDGF-BB: a retrospective consecutive case series. *Int J Periodontics Restorative Dent* 2013;33:437–445.

40. Torres J, Tamimi F, Alkhraisat MH, et. al. Platelet-rich plasma may prevent titanium-mesh exposure in alveolar ridge augmentation with anorganic bovine bone. *J Clin Periodontol* 2010;37:943–951.

41. Zubery Y, Nir E, Goldlust A. Ossification of a collagen membrane cross-linked by sugar: a human case series. *J Periodontol* 2008;79:1101–1107.

42. Dahlin C, Lindhe A, Gottlow J, Nyman S. Healing of bone defects by guided tissue regeneration. *Plast Reconstruct Surg* 1988;81:672–676.

43. Rosenquist JB, Noström E. Occlusion of the incisal canal with bone chips. A procedure to facilitate insertion of implants in the anterior maxilla. *Int J Oral Maxillofac Surg* 1992;21:210–211.

44. Artzi Z, Nemcovsky CE, Bitlitum I, Segal P. Displacement of the incisive foramen in conjunction with implant placement in the anterior maxilla without jeopardizing vitality of nasopalatine nerve and vessels: a novel surgical approach. *Clin Oral Implants Res* 2000;11:505–510.